

Diphallia: literature review and proposed surgical classification system

Dylan John Kendrick¹ and Roy Mark Kimble^{2,3}

¹School of Medicine, University of Queensland, Brisbane, Queensland, Australia

²Department of Paediatric Surgery, Urology, Burns & Trauma, Queensland Children's Hospital, Brisbane, Queensland, Australia and

³School of Health Sciences, Queensland University of Technology, Brisbane, Queensland, Australia

Key words

classification, congenital anomaly, diphallia, duplicate penis, urethral duplication.

Correspondence

Mr. Dylan John Kendrick, School of Medicine, University of Queensland, Brisbane, QLD, Australia.

Email: d.kendrick@uqconnect.edu.au

D. J. Kendrick BSc, MSc; **R. M. Kimble** MBChB, FRACS, FRCSP, MD.

This is an open access article under the terms of the [Creative Commons Attribution-NonCommercial-NoDerivs](https://creativecommons.org/licenses/by-nc-nd/4.0/) License, which permits use and distribution in any medium, provided the original work is properly cited, the use is non-commercial and no modifications or adaptations are made.

Accepted for publication 23 May 2022.

doi: 10.1111/ans.17846

Introduction

Diphallia or duplicate penis is an extremely rare embryological anomaly with a wide range of anatomic appearances ranging from small accessory tissues to complete duplications of the phallus, glans, urethras, and bladders, as well as an extensive list of associated abnormalities. The phalluses are usually unequal in size and positionally, can lie side by side, stacked on top of the other in the sagittal plane, or with little association to each other.¹ This paper assesses patients within the literature to summarize diphallia variants, as well as build on the existing classification of diphallia to include a more specific categorization of the phallus soft tissue, the urethral anatomy, and the bladder configurations to create a surgical classification system.

Background

Diphallia is estimated to occur in 1 out of 5–6 million births, with around 100 patients being reported within the literature. The oldest

Abstract

Background: Diphallia occurs once in 5–6 million births, with no two patients presenting with the same anatomical variation. Here we discuss a review of diphallia case reports, as well as present a new surgical classification system based on the soft tissue composition of the two phalluses, the anatomy of the urethra present within the most normal phallus and the bladder configuration.

Methods: Eighty-seven diphallia case reports were collected and analysed, excluding those presented in animals and articles that were non-English, with the results compiled to provide an in-depth reference of the specific anatomy found in diphallia patients and the associated abnormalities.

Results: Our proposed classification system was then applied to each patient and the most common configuration base on our classification system presented, along with commonly seen associated anomalies.

Conclusion: The reviewed cases represent a subset of the most unique diphallia patients; thus, several cases may be left unreported. Future reports can then be categorized, aiding as a reference, and potentially building on the classification, should the patient not fit into a specific group, leading to an expansion of the classification system.

published instance of diphallia was reported in 1609 by Johannes Jacob Wecker; 'in Bologna during public dissections the cadaver of a man who had a double penis', however the earliest pictorial record of diphallia dates back to 1862 in the Lupanar (Latin for brothel) in Pompeii, in which a painting on the wall depicted a completely diphallic man (Fig. 1).²

Embryology

Previously, Cecil³ submitted four embryological explanations for diphallia. The first includes the bladder, the prostatic urethra, and the penis being derived from a bilateral anlagen, which normally gives a single end product by fusion, meaning diphallia is a product of an incompletely fused anlagen. Next, diphallia may be an atavism, as snakes and lizards normally possess double penis or possibly represents a teratoid structure. Cecil also suggested that it may be a minor degree of duplication, much like supernumerary digits, of the individual.



Fig. 1. Pompeian Lupanar showing Priapus with a double phallus. Image from Galassi *et al.* accessed January third, 2021.

Hollowell *et al.* however affirm that these explanations are incomplete and suggests that that embryologically, the diphallia anomaly occurs in the fetus between the third and seventh week of gestation, in which an insult hampers normal functioning of the caudal cell mass of the fetal mesoderm at the time of the urogenital sinus separating from the genital tubercle into the penis. Complete diphallia may then stem from longitudinal duplication of the infraumbilical cloacal, with the subsequent mesodermal migration leading to the formation of two separate and complete sets of genital tubercles, genital folds, and genital swellings.^{3,4}

Treatment

Treatment of diphallia is typically approached on an individual basis, as no two patients within the literature are the same. The associated anomalies are a major cause of mortality in diphallia patients, and treatment is usually done in a stepwise manor, with corrections aimed at the anomalies, excision of the more abnormal phallus, excision of the urethra in instances of duplicate urethra, and excision or correction of either duplicate bladders or bladder exstrophy.¹ It may also be difficult to discern which phallus to excise, thus with the proposed classification system, a label can be used to drive the treatment approach, allowing a decision to be

made based on the more normal phallus, with the more normal urethral pathway and normal bladder configuration.

Methods

For this paper, a review of published diphallia patients was conducted by one reviewer. Google scholar and PubMed were analysed using key phrases diphallia, double penis, pseudophallia and bifid glans giving a total of 518 articles. Articles were screened based on title and abstract, making sure to include relevant case reports in humans, excluding articles in animals, duplicate articles and non-English articles. Following the screening of relevant inclusion and exclusion criteria, a total of 76 articles were analysed, which totalled 87 relevant diphallia patients found within the literature. Each patient was then analysed and presented in Table 1. From each patient, the unique anatomical variant for each was then examined. This included first addressing the age of the patient at the time of presentation, followed by categorizing the soft tissue structure of each phallus, the anatomy of the scrotum and testicles, as well as if there was a penoscrotal transposition. The reports were also analysed for their urethral anatomy, and if there was a hypospadias or epispadias present, as well as the bladder configuration. Lastly, the associated abnormalities were summarized based on the reviewers best clinical judgement. Each patient was then classified based on the proposed classification system below.

Classification

Schneider⁸⁰ has previously classified diphallia into four main categories:

- (1) Duplication of the glans alone
- (2) Bifid diphallia
- (3) Complete diphallia with each penis having two corpora cavernosa and a corpus spongiosum
- (4) Pseudodiphallia in which there is a rudimentary accessory atrophic penis existing independently of the normal penis

Our proposed classification is based on anatomical variants found within the literature on diphallia, which builds on Schneider's classification in order to provide a more specific description of the phallus soft tissue, as well as include a description of the pathway of the most normal urethra and the bladder configuration. The classification method has been proposed to be used to simplify the categorization of diphallia patients, using the system to classify the most intact phallus, the most normal urethra, and whether there is an additional surgical step regarding the bladder. The system will place the anatomy of diphallia into specific categories based on the structure of the phallus, the urethral anatomy and the bladder formations. Table 2 below displays the proposed categories.

Results

With a review of the literature, and application of the proposed classification system, common diphallia configurations can be displayed. While these individuals may still differ in terms of specific anatomy, such as the relation of the phalluses to one another, the

Table 1 Literature review of diphallia, associated anatomy and classifications

Author, Year	Age at definitive treatment	Number of corpora cavernosa	Hypospadias/Epispadias	Scrotum	Testes	Penoscrotal Transposition	Urethra	Bladder	Other anomalies	Classification
Acimi ⁵	3 yrs.	Phallus 1: 2 Phallus 2: 2	Hypospadias	Normal	Descended bilaterally	No	Duplicate	Single	Imperforate anus	1A α
Acimi ⁶	4 mo.	Phallus 1: 2 Phallus 2: 2	Hypospadias	Bifid	Descended bilaterally	No	Duplicate, one functional	Single	Unilateral Kidney agenesis Lumbosacral meningocele Ureterovesical duplication	1B α
Adair and Lewis ⁷	1 yr.	Phallus 1: 2 Duplicate Glans	N/A	Normal	Descended unilaterally	No	Single	Single	Umbilical hernia	7A α
Al-Herbish and Al-Samarrai ⁸	1 mo.	Phallus 1: 2 Phallus 2: 2	Hypospadias	Bifid	Descended bilaterally	No	Duplicate with bifurcation of one urethra	Single	Unilateral Kidney agenesis Unilateral Kidney agenesis Musculoskeletal anomalies Hemivertebra and absent first rib	1A α
Aihole, 2015 ⁹	1 yr.	Phallus 1: 2	N/A	Normal	Descended bilaterally	No	Duplicate	Single	Pre-axial polydactyly Solitary Kidney	7B α
Akgül <i>et al.</i> ¹⁰	4 yrs.	Duplicate Glans Phallus 1: 2 Phallus 2: 2	N/A	Normal	Descended bilaterally	No	Duplicate	Duplicate	Atrial septal defect Anal atresia Duplicate rectum, colon, cecum, appendix and terminal ileum	1A β
Aleem ¹¹	2 mo.	Phallus 1: 1 Phallus 2: 1	Epispadias	Bifid	Descended bilaterally	No	Single	Single	Rectovesical fistula	1D α
Alf ¹²	19 yrs.	Phallus 1: 1 Phallus 2: 2	N/A	Normal	Descended bilaterally	No	Single	Single	N/A	2A α
Arya <i>et al.</i> ¹³	31 yrs.	Phallus 1: 2 Phallus 2: 2	Epispadias	Bifid	Descended bilaterally	No	Duplicate, no urethral plates	Exstrophy	N/A	1D γ
Bakheet and Refa'ei ¹⁴	3 mo.	Phallus 1: 2 Phallus 2: 2	N/A	Bifid	Descended bilaterally	No	Duplicate	Single	N/A	1A α
Bakheet and Refa'ei ¹⁴	Neonate	Phallus 1: 2 Phallus 2: 2	N/A	Duplicate	Duplicate, descended bilaterally	No	Duplicate	Single	Duplicate colon, rectum, anus	1A α
Bhat <i>et al.</i> ¹⁵	1 yr.	Phallus 1: 2 Phallus 2: 2	Hypospadias	Bifid	Descended bilaterally	No	Duplicate, opening normally and into lateral wall of bladder	Single	N/A	1C α
Blanco ¹⁶	18 yrs.	Phallus 1: 2 Phallus 2: 2	Hypospadias	Normal	Descended bilaterally	No	Duplicate	Single	N/A	1A α
Cernach <i>et al.</i> ¹⁷	11 mo.	Phallus 1: 2 Phallus 2: 2	N/A	Bifid	Descended bilaterally	No	Duplicate	Duplicate	Duplicate anus, one imperforate hemivertebrae and diastasis of pubic symphysis	1A β
Chadha <i>et al.</i> ¹⁸	Neonate	Phallus 1: 2 Phallus 2: 2	N/A	Bifid	Descended into lateral compartments bilaterally	No	Bifurcation at prostatic urethra	Single	N/A	1A α
de Oliveira <i>et al.</i> ¹⁹	5 yrs.	Phallus 1: 2 Phallus 2: 2	N/A	Normal	Descended bilaterally	No	Duplicate, unilateral stenosis	Single	N/A	1B α
Deshpande ²⁰	2 yrs.	Phallus 1: 2	N/A	Bifid	Descended bilaterally	No	Duplicate	Single	N/A	1A α

Table 1 Continued

Author, Year	Age at definitive treatment	Number of corpora cavernosa	Hypospadias/Epispadias	Scrotum	Testes	Penoscrotal Transposition	Urethra	Bladder	Other anomalies	Classification
Dewan <i>et al.</i> ²¹	7 yrs.	Phallus 2: 2 Phallus 1: 2 Phallus 2: 2	N/A	Bifid	Descended unilaterally Descended unilaterally	No	Duplicate, opening normally and into lateral wall of bladder	Single	Imperforate anus	1A α
Djordjevic and Perovic ²²	15 mo.	Phallus 1: 2 Phallus 2: 2	Hypospadias	Bifid	Descended bilaterally	No	Duplicate	Duplicate	Symphyseal diastasis	1A β
Dunn <i>et al.</i> ²³	3 yrs.	Phallus 1: 2 Phallus 2: 2	N/A	Bifid	Descended bilaterally	No	Duplicate	Duplicate	N/A	1A β
Dutta <i>et al.</i> ²⁴	Neonate	Phallus 1: 2 Phallus 2: 2	N/A	Bifid	Descended bilaterally	No	Duplicate, pneumaturia	Duplicate	Pelvic kidney Anorectal atresia	1A β
Elsawy <i>et al.</i> ²⁵	1 mo.	Phallus 1: 2 Phallus 2: 2	N/A	Normal	Descended bilaterally	No	Duplicate, one hypoplastic	Single	Inguinal hernia Absent right thumb	4A α
Frollo <i>et al.</i> ²⁶	84 yrs.	Phallus 1: 2 Phallus 2: 2	Hypospadias	Normal	Descended bilaterally	No	No urethra in either phallus	Single	N/A	1C α
Gavali <i>et al.</i> ²⁷	5 yrs.	Phallus 1: 2 Duplicate Glans	Hypospadias	Normal	Descended bilaterally	No	Single	Single	Single Kidney agenesis	7B α
Ghafoori <i>et al.</i> ²⁸	5 yrs.	Phallus 1: 1 Phallus 2: 1	N/A	Normal	Descended bilaterally	No	Duplicate	Single	N/A	3A α
Goad <i>et al.</i> ²⁹	13 yrs.	Phallus 1: 2 Phallus 2: 2	Hypospadias	Normal	Descended bilaterally	No	Single	Single	N/A	1A α
Gupta and Virdi ³⁰	10 yrs.	Phallus 1: 2 Phallus 2: 2	N/A	Normal	Descended bilaterally	No	Duplicate	Single	N/A	1A α
Gyftopoulos <i>et al.</i> ³¹	Neonate	Phallus 1: 2	Hypospadias	Bifid	Undescended bilaterally	No	Duplicate	Duplicate	Horseshoe kidney Partial duplication of distal colon Ventricular septum defect	1A β
		Phallus 2: 2							Hypoplasia of the right leg due to agenesis of the fibula Cloacal opening at the perineum	
	Neonate	Phallus 1: 2 Phallus 2: 2	N/A	Normal	Descended bilaterally	No	Duplicate, one with blind ending	Duplicate	Urethrectomy Y-fistula	3A β
Hanine <i>et al.</i> ³²	8 yrs.	Phallus 1: 1 Phallus 2: 1	N/A	Normal	Descended bilaterally	No	Single	Single	N/A	2A α
Hollowell <i>et al.</i> ¹³	5 mo.	Phallus 1: 2 Phallus 2: 2	Hypospadias	Bifid	Descended bilaterally	No	Duplicate	Duplicate	Imperforate anus Perineal fistula	1A α
	50 yrs.	Phallus 1: 2	Hypospadias	Bifid	Descended into lateral compartments	No	Duplicate	Single	Meningocele Prolapse of the rectum Absence of perineal Midline infraumbilical musculature	1C α
Jesus <i>et al.</i> ³³	20 yrs.	Phallus 1: 2 Duplicate Glans	Hypospadias	Normal	Descended bilaterally	No	Duplicate	Single	Bilateral inguinal hernias	7C α

Table 1 Continued

Author, Year	Age at definitive treatment	Number of corpora cavernosa	Hypospadias/Epispadias	Scrotum	Testes	Penoscrotal Transposition	Urethra	Bladder	Other anomalies	Classification
Johnson <i>et al.</i> ³⁴	17 yrs.	Phallus 1: 2 Duplicate Glans	N/A	Normal	Descended bilaterally	No	Duplicate	Single	N/A	7A α
Karagöz <i>et al.</i> ³⁵	15 yrs.	Phallus 1: 2 Duplicate Glans	N/A	Normal	Descended bilaterally	No	Single	Single	N/A	7A α
Kardasevic <i>et al.</i> ³⁶	Neonate	Phallus 1: 2 Phallus 2: 2	Hypospadias	#NAME?	Descended bilaterally	No	Duplicate	Duplicate	Atrial and ventricular septal defect Duplicate right ureter Triple spleen Duplicate right kidney Omphalocele Tracheoesophageal fistula Imperforate anus Single Kidney agenesis Duplicate distal ileum, cecum, appendix and colon	1A β
Karna and Kapur ³⁷	Neonate	Phallus 1: 2	N/A	Bifid	Undescended bilaterally	No	Duplicate	Single	Imperforate anus	1A α
Kaufman <i>et al.</i> ³⁸	15 yrs.	Phallus 1: 2 Phallus 2: 2	Hypospadias	Normal	Descended bilaterally	No	Duplicate, with third perineal urethra	Single	Musculoskeletal anomalies Imperforate anus	1A α
Keckler ³⁹	Neonate	Phallus 1: 2 Phallus 2: 2	N/A	Normal	Descended bilaterally	No	Duplicate	Single	N/A	1A α
Kendrick <i>et al.</i> ⁴⁰	3 mo.	Phallus 1: 2 Phallus 2: 1	N/A	Normal	Descended bilaterally	Partial	Duplicate, opening normally and into lateral wall of bladder	Single	N/A	2B α
Khorramirouz <i>et al.</i> ⁴¹	6 yrs.	Phallus 1: 2 Duplicate Glans	N/A	Normal	Descended bilaterally	No	Duplicate, unilateral stenosis	Duplicate	Horseshoe Kidney	7B β
Kirli <i>et al.</i> ⁴²	Neonate	Phallus 1: 2 Phallus 2: 2	Epispadias	Normal	Descended bilaterally	No	Duplicate	Exstrophy	Inguinal hernia	1D γ
Kundal <i>et al.</i> ⁴³	3 yrs.	Phallus 1: 2 Phallus 2: 2	Epispadias	Normal	Descended bilaterally	No	Duplicate	Single	N/A	1A α
Landy <i>et al.</i> ⁴⁴	Neonate	Phallus 1: 2 Phallus 2: 2	N/A	Normal with accessory scrotum	Descended bilaterally	No	Duplicate	Single	Imperforate anus	1A α
Larsen ⁴⁵	14 yrs.	Phallus 1: 1 Phallus 2: 1	N/A	Normal	Descended unilaterally	Partial	Duplicate	Single	Atrophic leg	3A α
Leite <i>et al.</i> ⁴⁶	2 yrs.	Phallus 1: 1 Phallus 2: 1	N/A	Normal	Descended bilaterally	No	Duplicate, one with blind ending	Single	Short oesophagus	3A α
Maher <i>et al.</i> ⁴⁷	Neonate	Phallus 1: 2	N/A	Duplicate	Descended bilaterally	No	Duplicate	Duplicate	Separated natal clefts with no anal orifice Hydronephrotic left kidney Duplicated colon Caudal duplication syndrome	1A β
Mandal and Sahl ⁴⁸	Neonate	Phallus 1: 2	N/A	Duplicate	Descended bilaterally	No	Duplicate	Single	N/A	1A α

Table 1 Continued

Author, Year	Age at definitive treatment	Number of corpora cavernosa	Hypospadias/Epispadias	Scrotum	Testes	Penoscrotal Transposition	Urethra	Bladder	Other anomalies	Classification
		Phallus 2: 2			Duplicate, descended bilaterally					
Marti-Bonmati <i>et al.</i> ⁴⁹	Neonate	Phallus 1: 2 Phallus 2: 2	Hypospadias	Ectopic scrotal tissue	Descended unilaterally	No	Duplicate, one with blind ending	Exstrophy	Imperforate anus	1Aγ
Maruyama <i>et al.</i> ⁵⁰	Neonate	Phallus 1: 1	Hypospadias	Bifid	Descended unilaterally	No	Duplicate	Single	Tracheoesophageal fistula with oesophageal atresia Imperforate anus Bilateral radial limb defects Cleft palate Patent ductus arteriosus, Single umbilical artery Right megaureter Left multicystic dysplastic kidney	3Cα
		Phallus 2: 1								
Matsumoto <i>et al.</i> ⁵¹	12 mo.	Phallus 1: 1 Phallus 2: 2	Hypospadias	Bifid	Descended bilaterally	Complete	Duplicate	Single	Atrial septal defect	2Aα
Melekos <i>et al.</i> ⁵²	8 yrs.	Phallus 1: 1 Phallus 2: 1 Phallus 1: 1 Phallus 2: 1	Hypospadias	Normal	Descended bilaterally	No	Duplicate	Single	Horseshoe Kidney	6Cα
Mingazzini ⁵³	36 yrs.	Phallus 1: 1 Phallus 2: 1	N/A	Normal	Descended bilaterally	No	Duplicate, unilateral stenosis	Single	Umbilical hernia	3Aα
Mirshemirani <i>et al.</i> ⁵⁴	Neonate	Phallus 1: 2 Phallus 2: 2	Hypospadias	Bifid	Descended bilaterally	No	Duplicate	Duplicate	Imperforate anus Duplicate colon	1Cβ
		Phallus 1: 1 Phallus 2: 1	Hypospadias	Bifid	Descended bilaterally	No	Duplicate	Single	Imperforate anus Duplicate sigmoid colon	3Cα
		Phallus 1: 2 Phallus 2: 2	N/A	Normal	Descended bilaterally	No	Duplicate	Duplicate	Right inguinal hernia	1Aβ
		Phallus 1: 2 Phallus 2: 2	Epispadias	Bifid	Descended bilaterally	No	Duplicate	Exstrophy	Single kidney	4Dγ
		Phallus 1: 2 Phallus 2: 2	N/A	Bifid	Descended bilaterally	No	Duplicate	Duplicate	Hemi-Vertebra N/A	1Aβ
		Phallus 1: 2 Phallus 2: 2	N/A	Bifid	Descended bilaterally	No	Duplicate	Single	Imperforate anus	1Aα
Mukunda <i>et al.</i> ⁵⁵	Neonate	Phallus 1: 2 Phallus 2: 2	N/A	Bifid	Descended bilaterally	No	Bifurcation at prostatic urethra	Single	Meckel's diverticulum	1Eα
Mutlu <i>et al.</i> ⁵⁶	9 yrs.	Phallus 1: 2 Phallus 2: 1	N/A	Normal	Descended bilaterally	No	Bifurcation at prostatic urethra	Single	Rotational anomaly of right kidney Left ureter duplication	2Eα
Nunez <i>et al.</i> ⁵⁷	Neonate	Phallus 1: 2 Duplicate Glans	Hypospadias	Normal	Descended bilaterally	No	Duplicate	Single	Anorectal malformation	7Cα
Peiris ⁵⁸	17 yrs.	Phallus 1: 2 Phallus 2: 0	N/A	Normal	Descended bilaterally	No	Single	Single	N/A	2Aα
Priyadarshi ⁵⁹	1 yr.	Phallus 1: 1 Phallus 2: 1	Epispadias	Bifid	Descended bilaterally	No	Duplicate	Single	Ectopic bowel segment	3Dα
Rajarajan ⁶⁰	23 yrs.	Phallus 1: 2 Phallus 2: 2	N/A	Normal	Descended bilaterally	No	Duplicate	Single	Anorectal anomalies and colonic duplication	4Cα
Rao and Chandrasekharam ⁶¹	3 mo.	Phallus 1: 2 Duplicate Glans	Epispadias	Normal	Descended bilaterally	No	Single	Single	N/A	7Dα

Table 1 Continued

Author, Year	Age at definitive treatment	Number of corpora cavernosa	Hypospadias/Epispadias	Scrotum	Testes	Penoscrotal Transposition	Urethra	Bladder	Other anomalies	Classification
Remzli ⁶²	14 yrs.	Phallus 1: 2 Phallus 2: 2	Hypospadias	Duplicate	Duplicate, descended bilaterally	No	Duplicate, one with blind ending	Extrophy	hemivertebrae, lumbosacral scoliosis	1Cγ
Rock and Gearheart ⁶³	1 yr.	Phallus 1: 2 Phallus 2: 2	N/A	Bifid	Descended bilaterally	No	Duplicate	Duplicate	Hypoplastic kidney Widely separate pubic diastasis	1Aβ
Rodriguez ⁶⁴	Neonate	Phallus 1: 2 Phallus 2: 2	Hypospadias/Epispadias	Duplicate	Duplicate, descended bilaterally	No	Duplicate	Single (bilobated)	Duplicate umbilical cord	1Cα
Rossete-Cervantes and Villegas-Muñoz ⁶⁵	83 yrs.	Phallus 1: 2 Phallus 2: 2	N/A	Normal	Duplicate, descended bilaterally	No	Duplicate	Single	N/A	1Aα
Savir et al. ⁶⁶	31 yrs.	Phallus 1: 2 Phallus 2: 2	N/A	Normal	Descended bilaterally	No	Duplicate	Single	N/A	4Aα
Sharma et al. ⁶⁷	Neonate	Phallus 1: 2 Phallus 2: 2	N/A	Normal	Descended bilaterally	No	Duplicate, one with blind ending	Single	Duplicate colon	1Aα
Sharma et al. ⁶⁸	Neonate	Phallus 1: 2 Phallus 2: 2	N/A	Normal	Descended bilaterally	No	Duplicate, one with blind ending	Single	N/A	1Aα
Sina et al. ⁶⁹	2 mo.	Phallus 1: 2 Phallus 2: 1	N/A	Normal with accessory scrotum	Descended bilaterally	No	Duplicate	Single	N/A	2Aα
Smith and Sherer ⁷⁰	18 yrs.	Phallus 1: 2 Duplicate Glans	N/A	Normal	Descended unilaterally	No	Duplicate	Extrophy	N/A	7Aγ
Solomon et al. ⁷¹	Neonate	Phallus 1: 2 Phallus 2: 2	N/A	Normal	Descended unilaterally	No	Duplicate	Single	Supernumerary kidney	6Aα
Sotiropoulos et al. ⁷²	12 yrs.	Phallus 1: 2 Phallus 2: 2	Hypospadias	Bifid	Descended bilaterally	No	Duplicate, both blind ending	Extrophy	Hypoplastic kidney Omphalocele Bilateral inguinal hernia Imperforate anus Colovesical fistula	1Aγ
	14 yrs.	Phallus 1: 2 Duplicate Glans	Epispadias	Bifid	Descended bilaterally	No	Duplicate	Extrophy	Agnesis left upper extremity, and a web deformity of the left popliteal region. Rectoperineal fistula	7Cγ
	Neonate	Phallus 1: 2 Phallus 2: 2	N/A	Normal	Descended bilaterally	No	Duplicate	Extrophy	Vesicoureteral reflux	2Dγ
	17 yrs.	Phallus 1: 1 Phallus 2: 1	N/A	Normal	Descended bilaterally	No	Duplicate	Duplicate	Aplastic kidney Atrophic right kidney	6Aβ
Tepeler et al. ⁷³	14 yrs.	Phallus 1: 2 Phallus 2: 1	N/A	Bifid	Descended bilaterally	No	Duplicate	Single	N/A	2Aα
Tirtayasa et al. ⁷⁴	12 yrs.	Phallus 1: 2 Phallus 2: 2	Epispadias	Bifid	Descended bilaterally	No	Duplicate	Single	Ectopic bowel segment	1Dα
Tu et al. ⁷⁵	Neonate	Phallus 1: 2 Phallus 2: 2	N/A	Bifid	Descended bilaterally	No	Duplicate	Single	N/A	1Aα

Table 1 Continued

Author, Year	Age at definitive treatment	Number of corpora cavernosa	Hypospadias/Epispadias	Scrotum	Testes	Penoscrotal Transposition	Urethra	Bladder	Other anomalies	Classification
Vilanova and Raventos ⁷⁶	30 yrs.	Phallus 1: 2 Phallus 2: 1	N/A	Normal	Descended bilaterally	No	Single	Single	N/A	2A α
Wojewski and Kossowski ⁷⁷	6 yrs.	Phallus 1: 2 Phallus 2: 2	N/A	Duplicate	Duplicate, descended bilaterally	No	Duplicate	Duplicate	Talipes equinovarus Ureter stenosis	1A β
Zhang <i>et al.</i> ⁷⁸	23 yrs.	Phallus 1: 2 Duplicate Glans	N/A	Normal	Duplicate, descended bilaterally	No	Single	Single	N/A	7A α
Zolfaghari <i>et al.</i> ⁷⁹	4 mo.	Phallus 1: 2 Phallus 2: 2	Hypospadias	Normal	Descended bilaterally	No	Duplicate, one with blind ending	Single	Bilateral congenital hip dislocation, severe right talipes equinovarus and hypotrophy of the right lower limb. Inguinal hernia	1A α

Table 2 Proposed classifications of phallus, urethra and bladder found in Diphallia

Phallus	
Character	Type
Separate phalluses, 3 corpora each	1
Separate phalluses, 3 corpora in only one	2
Separate phalluses, neither contain 3 corpora	3
Phalluses contained within same shaft skin, 3 corpora each	4
Phalluses contained within same shaft skin, 3 corpora in only one	5
Phalluses contained within same shaft skin, neither contain 3 corpora	6
Bifid glans	7
Urethra to most normal phallus	
Character	Type
Normal urethra present	A
Urethral stenosis	B
Hypospadias	C
Epispadias	D
Bifurcation	E
Bladder	
Character	Type
Single	α
Double	β
Exstrophy	γ

Table 3 Proportion of diphallia anatomical variants within the literature

Classification	Count	Percent (%)
1A α	23	26.4
1A β	11	12.6
2A α	7	8.0
1C α	4	4.6
3A α	4	4.6
7A α	4	4.6
1A γ	2	2.3
1D α	2	2.3
1D γ	2	2.3
3C α	2	2.3
4A α	2	2.3
7B α	2	2.3
7C α	2	2.3
1B α	2	2.3
1C β	1	1.1
1C γ	1	1.1
1E α	1	1.1
2B α	1	1.1
2D γ	1	1.1
2E α	1	1.1
3A β	1	1.1
3D α	1	1.1
4C α	1	1.1
4D γ	1	1.1
6A α	1	1.1
6A β	1	1.1
6C α	1	1.1
7A α	1	1.1
7A γ	1	1.1
7B β	1	1.1
7C γ	1	1.1
7D α	1	1.1

specific pathway of the urethras or the associated anomalies, the classification and the frequency in which they occur is based on the soft tissue make-up of the phalluses, the urethra as it pertains to the

Table 4 Most common anatomical variants for diphallia

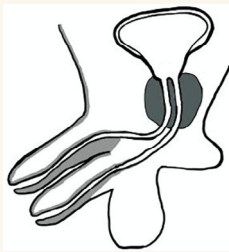

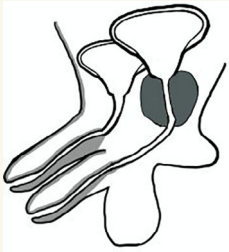

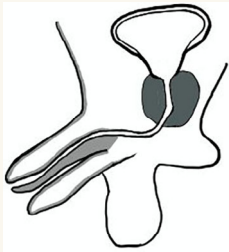

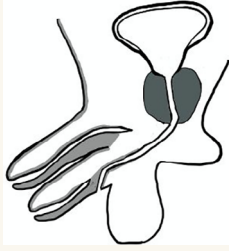
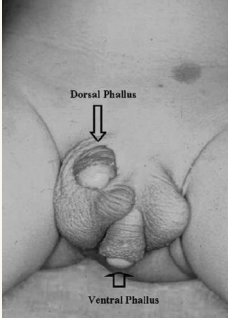
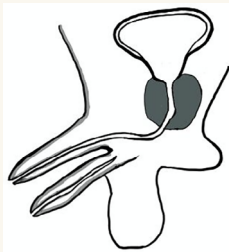

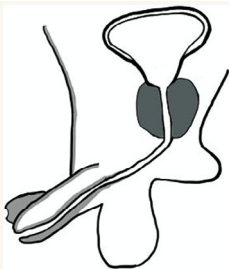

Classification	Diagram	Gross anatomy	References
1A α			Chadha <i>et al.</i> ¹⁸
1A β			Maher <i>et al.</i> ⁴⁷
2A α			Sina <i>et al.</i> ⁶⁹
1C α			Bhat <i>et al.</i> ¹⁵
3A α			Leite <i>et al.</i> ⁴⁶

Table 4 Continued

Classification	Diagram	Gross anatomy	References
7A α			Zhang <i>et al.</i> ⁷⁸

most normal urethra and the bladder configuration. Of the reviewed literature with sufficient information, our classification showed that diphallia patients categorized as 1A α contributed to the largest percentage of reports at 26.4%. The next most frequent pattern seen was 1A β , where the soft tissue and urethra were structurally normal, however there was a duplicate bladder, which made up 12.6% of the patients reviewed. The 2A α configuration was the next most seen classification within the literature, appearing in 7% or 8.0%, followed by configurations 1C α , 3A α , 7A α , which each contributed to 4.6% of the patients. The remaining reports and the corresponding classifications can be reviewed in Table 3. Table 4 then depicts the most common configurations found within the literature and additional examples of diphallia, which shows a graphic of the corresponding anatomy, an example of the gross anatomy extracted from their corresponding reference and the patient that correspond to the detailed classification.

Associated anomalies

Upon review of the literature, several diphallia patients present with no other associated anomalies. However, several abnormalities can be seen in other diphallia patients. These anomalies arise from both genitourinary and gastrointestinal systems, as well as some reports seeing musculoskeletal or cardiovascular anomalies. The majority of the malformations fall within the former two. Genitourinary abnormalities include the presence of either a duplicate bladder^{10,13,17,22–24,31,36,41,47,54,63,72} or bladder exstrophy,^{13,42,49,62,70,72,77} as well as duplicate ureters,^{36,56} vesicoureteral reflux,^{47,72} and ureteric stenosis.⁷⁷ Further anomalies within the urinary system include issues and malformations pertaining to the kidneys, which include single kidney agenesis,^{7–9,37,54,63,72} duplicate unilateral kidney,³⁶ pelvic kidney²⁴ and horseshoe kidney.^{31,41,52} Fistulas pertaining to the urinary system were also a common association with rectovesical and urethrorectal^{10,31,72} being noted. Next, there is also a wide range of gastrointestinal abnormalities that appear to arise in patients with diphallia. The most seen is the presence of an imperforate anus.^{5,13,17,24,37,38,44,47,49,50,54,72} There can also be further duplication of various aspects of the gastrointestinal system associated with diphallia, which includes duplication of the rectum, colon, cecum,

appendix, and terminal ileum.^{10,14,31,37,47,54,60,67} Along with the mentioned fistulas mentioned above, perineal¹³ and tracheoesophageal fistula^{37,50} have been reported as associated abnormalities pertaining to the gastrointestinal tract. It was also noted that there were hernias associated with diphallia patients, mostly those occurring at the umbilicus,^{7,25,41,53} however inguinal hernias^{54,72,79} are also cited within the literature. Further gastrointestinal anomalies then include ectopic bowel segments,^{59,74} omphalocele^{37,72} and Meckel diverticulum.⁵⁵

In terms of musculoskeletal and cardiovascular abnormalities, there is a wide range of malformations shown in the literature that

Table 5 Proportion of associated abnormalities

Associated Abnormality	Count	Percent (%)
<i>Gastrointestinal</i>		
Imperforate anus	12	13.8
GIT duplication	8	9.2
Anorectal malformation	5	5.7
Ectopic bowel segments	2	2.3
Omphalocele	2	2.3
Oesophageal atresia with tracheoesophageal fistula	2	2.3
Meckel diverticulum	1	1.1
<i>Genitourinary</i>		
Single renal agenesis	7	8.0
Horseshoe kidney	3	3.4
Duplicate ureters	2	2.3
Vesicoureteral reflux	2	2.3
Pelvic kidney	1	1.1
Duplicate kidney	1	1.1
Ureteric stenosis	1	1.1
<i>Muskuloskeletal</i>		
Limb agenesis/hypotrophy	5	5.7
Wide diastasis of pubic bone	4	4.6
Hemivertebra	3	3.4
Meningocele	2	2.3
Talipes equinovarus	2	2.3
Sacral agenesis	1	1.1
Bilateral hip dislocations	1	1.1
<i>Cardiovascular</i>		
Atrial septal defect	2	2.3
<i>Hernias</i>		
Inguinal	6	6.9
Umbilical	2	2.3

are associated with diphallia. Two common associations include both hemivertebra^{8,54,62} and a wide diastasis of the pubic bone^{11,17,22,63} with further musculoskeletal malformations comprising of menigocele^{6,13} and talipes equinovarus^{77,79} and less commonly pre-axial polydactyly,⁹ partial sacral agenesis,¹¹ agenesis and hypotrophy of digits or limbs,^{25,31,45,72,79} or bilateral congenital hip dislocations.⁷⁹ Cardiovascular malformations are more rare, however present in multiple patients, which include abnormalities such as atrial septal defects.^{9,51} A summary of associated abnormalities pertaining to specific patients is outlined in Table 1.

Table 5 then displays the most commonly seen abnormalities seen in concordance with diphallia. Most commonly, an imperforate anus was seen associated with diphallia patients which was shown in 13.8% of the reviewed patients. Next, 9.2% of the patients also saw further duplication along the gastrointestinal tract, with duplications of either the rectum, colon, cecum, appendix or terminal ileum being reported. Single kidney agenesis and inguinal hernias were then the next most seen abnormalities, arising in 8.0% and 6.9% of the patients, respectively. Lastly, the most common musculoskeletal anomaly associated with diphallia was limb agenesis or hypotrophy, which appeared in 5.7% of the diphallia cases.

Discussion

The paper highlights an overview of diphallia, illustrating different aspects of the anomaly including history, embryology and treatments. It also expands to provide a classification system that is built on previous works to give a system in which future patients can be categorized and compared. The results then feature the most common anatomical variations, showing that roughly 25% of the published instances have two phalluses with 3 corpora, at least a single normal urethra and a single bladder. The literature review and the published articles however may be biased as typically the more unique and interesting patients are presented, leaving a potentially large number of unpublished reports that could contribute to the current review and proposed classification system. The results regarding associated anomalies potentially hold a similar bias, in that unique abnormalities may have been focused on, leaving out seemingly minute associations. Lastly, as new patients may be presented, and different variants may arise in which the proposed classification system may or may not encompass, or penile anomalies such as triphallia or triple penis, as reported by Jabali *et al.*⁸¹ get reported, the current proposed classification may need to be modified.

Conclusion

Following a literature review, each diphallia patient is a unique variant with its own anatomical configuration and associated anomalies. This has led to the proposed classification system that builds on previous bodies of work to categorize each patient based on the most normal aspects of the diphallia. By classifying the structure of the phallus that is to be kept, the pathway of the urethra present within the most normal phallus and the bladder morphology, a surgical approach can be broached and executed to ensure a

satisfactory functional goal, with preserved continence, erectile function, and cosmetic outcomes.

Conflict of interest

The review is not registered, and the protocol was not prepared. Support from the Paediatric Surgery and Urology Department at the Queensland Children's Hospital. None declared.

Author contributions

Dylan John Kendrick: Conceptualization; data curation; formal analysis; investigation; methodology; visualization; writing – original draft; writing – review and editing. **Roy Mark Kimble:** Project administration; supervision; writing – review and editing.

References

- Fahmy M. *Congenital anomalies of the penis*. Springer International Publishing Switzerland, 2017. Penile Duplication, pp. 73–8.
- Galassi FM, Henneberg M, Habicht ME, Rühli FJ. Diphallia in the ancient world: insights from a pompeian fresco (70-79 AD). *Urology* 2016; **22**: 281–2.
- Cecil AB. *Anatomy, anomalies and injuries of the penis*, Vol. **162**. H. Cabot. Philadelphia: Lea & Febiger, 1936.
- Hollowell F Jr, Witherington R, Ballagas AJ *et al.* Embryological consideration of diphallus and associated anomalies. *J. Urol.* 1977; **111**: 728–32.
- Acimi S. Complete diphallia. *Scand. J. Urol. Nephrol.* 2004; **38**: 446–7.
- Acimi S. Complete diphallia. *Scand. J. Urol. Nephrol.* 2008; **42**: 389–91.
- Adair EL, Lewis EL. Ectopic scrotum and diphallia: report of a case. *J. Urol.* 1960; **84**: 115–7.
- Al-Herbish A, Al-Samarrai AY. Diphallus associated with a third ectopic urethra. *Pediatr. Surg. Int.* 1996; **11**: 189–90.
- Aihole JS, Babu N, Shankar G. Glandular diphallus with urethral duplication: conventional technique for a rare congenital anomaly. *Indian J. Urol.* 2015; **31**: 369–71.
- Akgül AK, Uçar M, Çelik F, Kırsıtoğlu İ, Kılıç N. Complete penile duplication with structurally normal penises: a case report. *Balkan Med. J.* 2018; **35**: 340–3.
- Aleem AA. Diphallia: report of a case. *J. Urol.* 1972; **108**: 357–8.
- Ali MT. Case report: supernumerary penis (diphallia terrata). *Int. J. Collab. Res. Int. Med. Public Health* 2012; **4**: 502–5.
- Arya MC, Gandhi A, Singhal A, Vasudeo V, Singh R, Sonwal M. True diphallia: a report of two cases. *Asian J. Res. Rep. Urol.* 2020; **1**: 1–4.
- Bakheet MA, Refaei M. Penile duplication and two anal openings; report of a very rare case. *Iran. J. Pediatr.* 2012; **22**: 133–6.
- Bhat HS, Sukumar S, Nair TB, Saheed CS. Successful surgical correction of true diphallia, scrotal duplication, and associated hypospadias. *J. Pediatr. Surg.* 2006; **41**: e13–4.
- Blanco S. Diphallus (double penis). *J. Urol.* 1945; **53**: 786–90.
- Cernach MC, Hayashi H, Soares D. Diphallia associated with malformation of hindgut derivatives. *Urology* 1989 Mar 1; **33**: 209–10.
- Chadha R, Bagga D, Gupta S, Mahajan JK. Complete diphallia associated with features of covered exstrophy. *J. Pediatr. Surg.* 2001; **36**: 1–3.

19. de Oliveira MC, Ramires R, Soares J, Carvalho AP, Marcelo F. Surgical treatment of penile duplication. *J. Pediatr. Urol.* 2010; **6**: 257–e1.
20. Deshpande V. Complete diphallia—Our technique to avoid complications. *J. Indian Assoc. Pediatr. Surg.* 2020; **25**: 182–3.
21. Dewan PA, Lawrence MJ, Pip A, Kasa S. Diphallus associated with partial caudal duplication. *Pediatr. Surg. Int.* 1998; **14**: 131–3.
22. Djordjevic ML, Perovic SV. Complex penile joining in a case of wide penile duplication. *J. Urol.* 2005; **173**: 587–8.
23. Dunn D, Fine RG. Diphallia, double bladder, and two hemiscrotums: a case report. *AORN J.* 2019; **109**: 728–40.
24. Dutta T, George V, Meenakshi PK, Das G. Rare combination of duplication of genito-urinary tract, hindgut, vertebral column and other associated anomalies. *Br. J. Urol.* 1974; **46**: 577–82.
25. Elsayy M, Salle JL, Abdulsalam M, Alsaid AN. Penile duplication: is it necessary to excise one of the penises? *J. Pediatr. Urol.* 2012; **8**: 434–6.
26. Frolov A, Tan Y, Rana MW, Martin JR. A rare case of human diphallia associated with hypospadias. *Case Rep. Urol.* 2018; **13**: 2018–6.
27. Gavali JS, Deshpande AV, Sanghani HH, Hirugade ST, Talpallikar MC, Borwankar SS. Glanular diphallus with urethral stricture. *Pediatr. Surg. Int.* 2002; **18**: 70–1.
28. Ghafoori M, Varedi P, Hosseini SJ. MRI in the diagnosis of diphallia. *Pediatr. Radiol.* 2007; **37**: 1298–300.
29. Goad EA, Chetty P, Berezcky ZB. Diphallia: report of a case. *Afr. J. Urol.* 2001; **7**: 114–117.
30. Gupta M, Virdi VJ. Rare case of isolated true complete diphallus—case report and review of literature. *BMJ Case Rep* 2013; **2013**: bcr2012008117.
31. Gyftopoulos K, Wolffenbuttel KP, Nijman RJ. Clinical and embryologic aspects of penile duplication and associated anomalies. *Urology* 2002; **60**: 675–9.
32. Hanine D, Aboulam Z, Oulahyane R, Kisra M. Diphallia—about an exceptional case & review of literature. *Scholars J. Med. Case Rep.* 2018; **6**: 905–9.
33. Jesus LE, Dekermacher S, Lopes E, Bacon AP. Glans duplication: in-depth review and proposal of a new classification. *J. Pediatr. Urol.* 2017; **13**: 172–6.
34. Johnson CF, Carlton CE Jr, Powell NB. Duplication of penis. *Urology* 1974; **4**: 722–5.
35. Karagöz Y, Fenjanchi I, Barut HY, Buker A, Barut AY. Isolated penile duplication: case report and literature. *Review* 2014; **3**: 762.
36. Kardasevic M, Begic F, Sivic M. Penile duplication in newborn with multiple anomalies. *Med. Arch.* 2012; **66**: 206.
37. Karna P, Kapur S. Diphallus and associated anomalies with balanced autosomal chromosomal translocation. *Clin. Genet.* 1994; **46**: 209–11.
38. Kaufman A, Guia R, Davila H, Kaufman A. Diphallus with third urethra. *Urology* 1990; **35**: 257–60.
39. Keckler S, Stephany HA, Spilde TL, Snyder CL. Isolated diphallia: case report and literature review. *Eur. J. Pediatr. Surg.* 2009; **19**: 254–5.
40. Kendrick DJ, Goddard LE, Kimble RM. Abnormal urethral pathways in a child presenting with diphallia. *J. Pediatr. Surg. Case Rep.* 2021; **1**: 101802.
41. Khorramirouz R, Bagheri A, Kajbafzadeh AM. Unusual variant of coronal bladder duplication associated with glans diphallia: a case report and review of the literature. *Case Rep. Urol.* 2015; **31**: 2015–4.
42. Kırılı E, Güçer Ş, Akçören Z, Karnak İ. Covered exstrophy with ectopic intestinal tissue and bifid phallus: one-stage repair of a complex abnormality. *J. Pediatr. Surg.* 2011; **46**: e1–3.
43. Kundal VK, Gajdhar M, Shukla AK, Kundal R. A rare case of isolated complete diphallia and review of the literature. *Case Rep.* 2013; **2013**: bcr2012008117.
44. Landy B, Signer R, Oetjen L. A case of diphallia. *Urology* 1986; **28**: 48–9.
45. Larsen J. Case report of a boy with penoscrotal transposition, double urethra, pseudodiphallia, and ectopic scrotum. *Teratology* 1990; **41**: 253–5.
46. Leite MT, Fachin CG, de Albuquerque Maranhão RF, Shida ME, Martins JL. Penile duplication without removal of corporal tissue: step by step of an excellent cosmetic result. *J. Pediatr. Urol.* 2014; **10**: 567–70.
47. Maher A, Sabra TA, Ibrahim H, Mostafa M. Newborn with complete double penis and two separate scrotums: a case report. *Int. J. Surg. Case Rep.* 2020; **1**: 490–7.
48. Mandal A, Sahi PK. Complete Diphallus. *BAOJ Pediatr.* 2017; **3**: 39.
49. Marti-Bonmati L, Menor F, Gomez J, Cortina H, Ibarra FG. Value of sonography in true complete diphallia. *J. Urol.* 1989; **142**(2 Part 1): 356–7.
50. Maruyama K, Takahashi A, Kobayashi T, Hatakeyama S, Matsuo Y. Diphallia and the Vater association. *J. Urol.* 1999; **162**: 2144.
51. Matsumoto F, Onitake Y, Matsui F, Shimada K. A case of bifid phallus and bladder neck incompetence: is this a variant of epispadias or hypospadias? *Urology* 2016; **1**: 186–8.
52. Melekos MD, Barbaliás GA, Asbach HW. Penile duplication. *Urology* 1986; **27**: 258–9.
53. Mingazzini E. A case of double penis. *Urol. Int.* 1955; **1**: 188–90.
54. Mirshemirani AR, Sadeghyian N, Mohajezadeh L, Molayee H, Ghaffari P. Diphallus: report on six cases and review of the literature. *Iran. J. Pediatr.* 2010; **20**: 353–7.
55. Mukunda R, Bendre PS, Redkar RG, Hambarde S. Diphallus with anorectal malformation—case report. *J. Pediatr. Surg.* 2010; **45**: 632–4.
56. Mutlu N, Baykal M, Merder E, Culha M, Canbazoğlu N. Diphallus with urethral duplications. *Int. Urol. Nephrol.* 1999; **31**: 253–5.
57. Núñez R, Blesa E, Vázquez F, Cabrera R. Incomplete diphallus: correction in one stage. *Pediatr. Surg. Int.* 1996; **11**: 412–3.
58. Peris V, Cuevas E, Quilis L. Pseudodiphallia. *Int. J. Dermatol.* 1992; **31**: 119–21.
59. Priyadarshi S. Diphallus with ectopic bowel segment: a case report. *Pediatr. Surg. Int.* 2005; **21**: 681–3.
60. Rajarajan J. Penile duplication—a super rarity. *Univ. J. Surg. Surg. Special.* 2020; **6**: 6.
61. Rao TV, Chandrasekharam V. Diphallus with duplication of cloacal derivatives: report of a rare case. *J. Urol.* 1980; **124**: 555–7.
62. Remzi D. Diphallia. *Urology* 1973; **1**: 462–3.
63. Rock SD, Gearhart JP. Complete lower urinary tract duplication with true diphallia presenting as a rare covered exstrophy variant. *J. Urol.* 1997; **157**: 1907–8.
64. Rodriguez C. Report of a case of diphallus. *J. Urol.* 1965; **94**: 436–8.
65. Rossete-Cervantes HE, Villegas-Muñoz A. Diphallia: a case report. *Revista Médica del Instituto Mexicano del Seguro Social.* 2016; **54**(3):401.
66. Savir A, Lurie A, Lazebnik J. Diphallia: report of a case. *Br. J. Urol.* 1970; **42**: 498–500.
67. Sharma N, Gupta S, Goyal M, Sattavan S. Complete Diphallia with no other associated congenital anomaly. *IP Int. J. Med. Paediatr. Oncol.* 2017; **3**: 136.
68. Sharma SP, Gangopadhyay AN, Gupta DK, Gopal SC, Dash RN, Sinha CK. A rare association of diphallus, colonic duplications, ileal atresia, and an anorectal malformation. *Pediatr. Surg. Int.* 1996; **11**: 414–5.
69. Sina A, Kajbafzadeh AM, Elahi E, Sina A, Sabetkish S, Piri S. Prenatal diagnosis of concomitant accessory scrotum and diphallia in the accessory tissues: case report. *Urology* 2019; **1**: 217–20.
70. Smith JR, Sherer JF. Diphallia: report of a case. *J. Urol.* 1965; **94**: 586–8.

71. Solomon AA, Rosenthal I, Linker MH. Double penis associated with supernumerary kidney. *J. Urol.* 1950; **64**: 705–9.
72. Sotiropoulos A, Uson A, Lattimer JK. Duplication of external genitalia in men. *Urology* 1974; **4**: 688–92.
73. Tepeler A, Karadağ MA, Özkuvancı Ü, Sarı E, Berberoğlu Y, Müslümanoğlu AY. Complete diphallus in a 14 years old boy.
74. Tirtayasa PM, Prasetyo RB, Rodjani A. Diphallia with associated anomalies: a case report and literature review. *Case Rep. Urol.* 2013; **8**: 2013–4.
75. Tu YA, Su YN, Yang PK, Shih JC. Prenatal diagnosis of true diphallia and associated anomalies. *Obstetr. Gynecol.* 2014; **124**: 416–8.
76. Vilanova, X, Ra Ventos A. Pseudodiphallia: a rare anomaly. *J. Urol.* 1954. **71**, 338, 346
77. Wojewski A, Kossowski W. Total diphallia: a case of plastic repair. *J. Urol.* 1964; **91**: 84–6.
78. Zhang W, Yu N, Liu Z, Wang X. Pseudodiphallia: a rare kind of diphallia: a case report and literature review. *Medicine* 2020; **99**: e21638.
79. Zolfaghari A, Pourissa M, Hajjalilou S, Amjadi M. True complete Diphallia: case report. *Scand. J. Urol. Nephrol.* 1995; **29**: 233–5.
80. Schneider P, Lamitter JK, Uson AC, Melicow AC. The male genital tract. In: Mustard WT, Ravitch MM, Snyder WH et al. (eds). *Pediatric Surgery*, 2nd edn. Chicago: Year Book Medical Publishers, 1969; 1263.
81. Jabali SS, Mohammed AA. Triphallia (triple penis), the first reported case in human. *Int. J. Surg. Case Rep.* 2020; **1**: 198–200.